

ORIGINAL ARTICLE

Adjustable Continence Therapy for the treatment of male stress urinary incontinence: A single-centre study

ERVIN KOCJANCIC, SIMONE CRIVELLARO, STEFANIA RANZONI,
DANIELE BONVINI, PAOLO GONTERO & BRUNO FREA

Clinica Urologica, Ospedale Maggiore della Carita, Novara, Italy

Abstract

Objective. To evaluate the Adjustable Continence Therapy (ProACT™) device, a new device for the treatment of male stress urinary incontinence resulting from compromised sphincteric function. **Material and methods.** A total of 64 males with post-prostatectomy incontinence underwent ProACT implantation. Efficacy was assessed by means of a daily pad count, a direct visual stress test, administration of the Incontinence Quality of Life (IQOL) and patient global impression (PGI) questionnaires and use of a visual analogue scale (VAS) to assess improvement in incontinence. These assessments were performed at baseline, 1, 3, 6 and 12 months after the procedure and annually thereafter. **Results.** The pad count declined from a median of 5.2 at baseline to 2 at 6 months and to 1.54 at 12 months. The median baseline IQOL score was 31.7, and this improved to 62.5 at 6 months and to 71.1 at 12 months. In terms of postoperative daily pad usage, 43 patients (67%) were considered to be dry, 10 (15%) improved and 11 (17%) unchanged. In terms of the postoperative PGI score, 43 patients (66%) considered themselves to have improved greatly, 10 (16%) to have improved quite a lot, 6 (9%) to have improved slightly and 6 (9%) to be unchanged. The average improvement based on the VAS was 80%. The average number of postoperative adjustments was three (range zero to nine). Complications included infection (2/64; 3%), erosion of balloons (5/64; 7.6%), migration (2/64; 3%) and balloon deflation (2/64; 3%). Device removal was required in 9/64 patients (14%) but was easily achieved using local anaesthesia, and this thus permitted further therapeutic intervention. Usually, new balloons were implanted following endoscopic confirmation of urethral healing. **Conclusion.** The ProACT device represents an efficacious treatment modality, which has an acceptable complication rate for a difficult group of patients.

Key Words: *Stress urinary incontinence, adjustability, prostatectomy, balloons, quality of life*

Introduction

There have been varying reports [1,2] concerning the incidence and severity of post-prostatectomy incontinence (PPI), depending on the surgical technique and individual definitions of incontinence [3]. About 6% of patients with PPI experience symptoms severe enough to warrant further surgical intervention [4]. The Artificial Urinary Sphincter (American Medical Systems, Minnetonka, MN) is considered the gold standard of surgical intervention [5]; however, its global adoption has been limited somewhat by its cost, the invasiveness of the technique, and therefore the skill required by the surgeon to perform the procedure and manage the complications, as well as the need for patient participation in the use of the device [6,7].

Material and methods

The Adjustable Continence Therapy (ProACT™) device, developed by Uromedica Inc. (Plymouth, MN) for the treatment of male stress urinary incontinence (SUI), is a minimally invasive treatment for this condition, which possesses the unique feature that it can be postoperatively adjusted if required. It consists of two silicone elastomer balloons which are placed para-urethrally at the bladder neck (in post-radical prostatectomy patients) or at the level of the membranous urethra (in patients who have residual prostatic tissue following benign surgery). Each balloon is attached via a conduit to a titanium port buried in the anterior lateral aspect of the scrotum. Postoperative adjustment of the balloons is facilitated by percutaneous injection of the

port after a minimum of 4 weeks postoperatively, with a 4-week interval being required between further adjustments. The implant is available in 12- and 14-cm lengths and each balloon can be inflated to a volume of 8 cm³ over time if necessary. The ProACT device can be simply inserted using general, spinal or local anaesthesia as required.

The procedure was performed using a similar technique to that reported by Hubner and Schlarp [8] and by Trigo Rocha et al. [9]. With the patient in the lithotomy position, the bladder is emptied and filled with 100 cm³ of contrast solution. The filling cystoscope is retained to maintain horizontal positioning of the urethra. Two small perineal stab incisions are made on each side of the urethra to allow passage of the balloons via designated blunt and sharp trocars and an outer cannula. The trocar is designed to perforate the pelvic floor and is gently rotated so that it advances towards the bladder neck or membranous urethra as appropriate. Image intensification is used to identify the position of the trocar in relation to the urethra and the desired final position of the trocar. Once in position, the trocar is removed and a tissue-expanding device is inserted through the U-shaped channel of the cannula. This device dilates only the area where the balloon will be inflated. The choice of device length is generally made based on the individual anatomical configuration of the patient. Prior to insertion, the device is primed to remove all air and is soaked briefly in antibiotic solution. The trocar is removed and the balloon inserted with the assistance of a push wire. Once in position, the balloon is inflated using an isotonic mixture of contrast medium and water using a dedicated non-coring 23 G needle and syringe. The process is repeated on the contralateral side. A urethrogram should be performed to verify the positions of the balloons and a 12 F Foley catheter inserted overnight. A superficial pocket is created in the sub-dartos fascia of the anterior lateral aspect of the scrotum, taking care to ensure that the ports are well separated and able to be easily accessed during postoperative adjustments.

We set out to evaluate this procedure in a group of males with urodynamic SUI who met the selection criteria. Inclusion criteria included being able and willing to provide informed consent and undergo follow-up. Patients were excluded if they had poor bladder compliance, an overactive or unstable bladder, a current bladder tumour or stones. Whilst PPI was the major reason for patient presentation, this was not a specific inclusion criterion, and men with other aetiologies were also invited to join the study. Following ethics committee approval (No. 2000D-9131), patients were enrolled and implanted with the ProACT device. Patients were evaluated

using a daily pad count (0–1 safety pad/day = dry; ≥ 2 pads/day but $> 50\%$ pad reduction = improved; and ≥ 2 pads/day and $< 50\%$ pad reduction = failure), administration of the Incontinence Quality of Life (IQOL) [10] and patient global impression (PGI) [11] questionnaires and use of a visual analogue scale (VAS) [12] to assess improvement in incontinence. These assessments were performed at baseline, 1, 3, 6 and 12 months after the procedure and annually thereafter. Additionally, adverse events, number of adjustments, balloon volumes and the overall patient impression based on a global assessment score [ranging from 1 (greatly improved) to 7 (very much worse) using the PGI questionnaire] were determined at each of the postoperative visits. Urodynamic evaluation of Valsalva leak point pressures and measurement of mean urethral closure pressure were performed at baseline and a direct visual stress test was performed at baseline and at each postoperative visit.

Results

Sixty-four male patients were implanted with the ProACT device between July 2000 and September 2004, and all patients have now had > 12 months follow-up. The mean follow-up period was 19.51 months (range 12–62 months). The mean age of patients at the time of implantation was 65.4 years (range 25–79 years). All patients had undergone previous prostatic surgeries that resulted in SUI an average of 4.4 years (range 1–12 years) previously. Seven patients (10%) had undergone a number of secondary procedures that may have further exacerbated their incontinence and six men (9.2%) had undergone one or more previous procedures to treat their urinary incontinence. The relevant previous surgical histories of the patients are shown in Table I.

The mean operative time was 19 min (range 10–35 min). All patients underwent implantation of the ProACT balloons using spinal anaesthesia. Blood loss was < 20 ml in each case. Analgesia was not required postoperatively and patients were discharged on average 1.1 days (range 1–2 days) after implantation. Foley urethral catheters were usually removed within 24 h postoperatively, but were retained for 4 days (range 3–5 days) if operative bladder perforation had occurred.

Table II shows the statistical improvement in quality of life based on IQOL score at each time point, and the trend in this improvement is shown in Figure 1.

Table II shows statistically significant changes in daily pad count over time. Figure 2 demonstrates the reduction in pad usage at each postoperative visit. Importantly, 68% of patients were pad-free (dry) at

Table I. Initial causes of PPI and subsequent anti-incontinence surgery.

Original surgery	Secondary procedure	Previous incontinence treatments
Radical retropubic prostatectomy, <i>n</i> = 57 (87%)	Bladder neck incision or internal urethrotomy, <i>n</i> = 7 (including three tertiary procedures) (10%) Radiotherapy, <i>n</i> = 11 (17%)	Bulking agents (including Macroplastique), <i>n</i> = 5 (8%) Artificial urinary sphincter (removed following erosion), <i>n</i> = 1 (1.5%)
Radical perineal prostatectomy, <i>n</i> = 1 (1.5%)		
Transurethral prostatectomy (including HIFU), <i>n</i> = 3 (4.6%)		
Open prostatectomy, <i>n</i> = 2 (3%)		
Cystectomy and creation of neobladder, <i>n</i> = 1 (1.5%)		

HIFU = high-intensity focused ultrasound.

Table II. Changes in pad use and quality of life with time.

Time (months)	IQOL score			Pad usage		
	Mean	SD	<i>p</i>	Mean	SD	<i>p</i>
0	31.7			5.2		
1	40.5	21.09	0.000063	3.55	3.29	0.000037
3	51.3	23.8	<0.0001	2.45	3.15	<0.0001
6	62.5	25.7	<0.0001	2.01	2.83	<0.0001
12	71.1	23.89		1.54	3.01	<0.0001

the last follow-up. Patient improvement based on global assessment (PGI score) and VAS score are described in Figures 3 and 4, respectively.

Adjustments were required in 61 patients (95%), with a median number of adjustments of 3 (range 0–8). The mean final balloon volume was 3.1 ml (range 1–8 ml).

Complications necessitating balloon removal occurred in 11 patients (17%), and there were two bilateral and nine unilateral removals. Balloon removal was required as a result of erosion (*n* = 5), infection (*n* = 2), migration (*n* = 2) and balloon failure (*n* = 2). Nine patients required balloon removal within 6 months, and the remaining two patients required it after ≥ 6 months. Ten patients were subsequently re-implanted at least 6 weeks later: two became dry, six improved (one of whom required an

underwear liner) and two were unchanged. No patients were worse following reimplantation. Operative bladder perforation occurred in 5 patients (7.6%) but was managed by way of a mean 4-day (range 3–5 days) urethral catheterization period, without further sequelae.

Eleven patients had previously undergone external-beam radiotherapy prior to implantation of their balloons: 4 (36.3%) were dry following adjustment, 2 (18.2%) were improved and 5 (45.5%) were unchanged compared to baseline at the last follow-up visit.

Three of these patients required removal of single balloons due to erosion: 80% of these cases occurred within 6 months following surgery, with the remaining 20% occurring at 12 months. The volume of the balloons at the time of erosion was equally

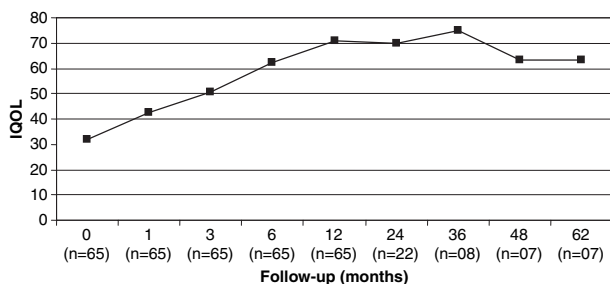


Figure 1. Changes in IQOL score with time.

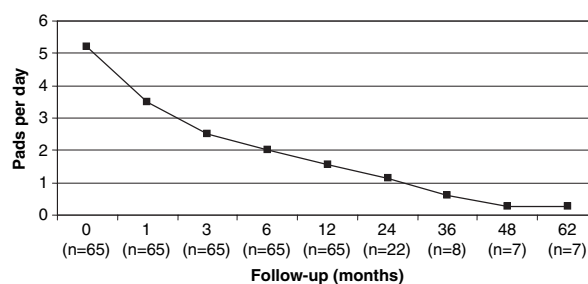


Figure 2. Changes in daily pad count with time.

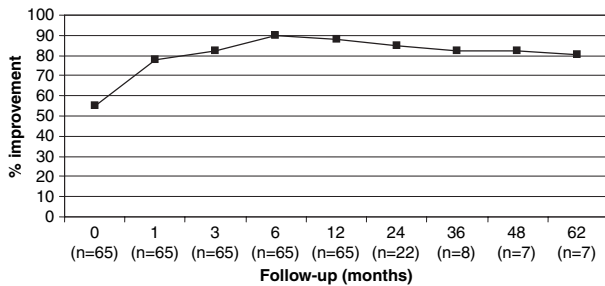


Figure 3. Changes in VAS score with time.

distributed in the range 1.5–7 ml and was not statistically significant based on a 95% CI.

Three patients had pre-existing sensory urgency. Postoperatively, four de novo cases were reported, but all seven of these patients experienced resolution of symptoms following short-term anticholinergic therapy within 1 month of surgery.

Discussion

The outcomes of this study raise some interesting points. Firstly, the preliminary results appear to demonstrate that implantation of the ProACT device may offer relief of symptoms in men with SUI resulting from different causes.

In our experience, the implantation procedure was easy both to perform and to reverse when necessary. Interestingly, during implantation of the ProACT balloons it was noted that those patients with titanium haemoclips in the pelvic area presented with more severe incontinence and had more scar tissue, making placement of the balloons more challenging.

Although we had implanted a number of patients prior to commencement of the study, our placement technique improved with experience, thereby reducing the incidence of procedural-related complications. Additionally, analysis of the results highlighted those patients more likely to experience complications, such as those who had undergone previous radiotherapy. In terms of these irradiated patients, although the success rate was less than that in the overall group the dry/improved rate of 57% was

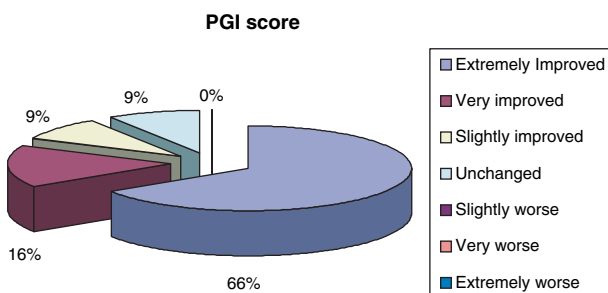


Figure 4. Distribution of PGI scores at last follow-up.

encouraging. The main complication in the irradiated patients was early erosion, which occurred almost exclusively within this group. Reassuringly, however, resolution was easy, with uncomplicated removal of the device being possible in an outpatient setting without further sequelae. Conservative balloon inflation and adjustment regimens should be adhered to in post-radiotherapy patients. The ability to make postoperative adjustments was of great benefit and, as shown by the numbers of adjustments performed, was a well-utilized feature.

Other available therapeutic options, such as the Artificial Urinary Sphincter [13], bulbar slings [14] and injectable bulking agents [15], provide varying rates of initial success using different approaches. Whilst a few slings may be adjusted during a secondary procedure [16], none have the ability to be adjusted over time without surgical intervention to maintain efficacy or offer the easy reversibility of the ProACT device. For these reasons we think that the ProACT device may become well accepted from the patient's perspective as a first-line treatment option.

We will continue to offer the ProACT device as a first-line surgical therapy for our patients, and to further evaluate the long-term outcomes of our already implanted males.

Acknowledgement

The authors thank Deborah Bell for her editorial assistance.

References

- [1] Majoras A, Bach D, Keszthelyi A, Hamvas A, Romics I. Urinary incontinence and voiding dysfunction after radical retropubic prostatectomy (prospective urodynamics study). *Neurourol Urodyn* 2006;25:2–7.
- [2] Walsh P, Partin A, Epstein J. Cancer control and quality of life following anatomical radical retropubic prostatectomy: results at 10 years. *J Urol* 1994;152:1831–6.
- [3] Pfister C, Cappele O, Dunet F, Bugel H, Grise P. Assessment of the intrinsic urethral sphincter component function in postprostatectomy urinary incontinence. *Neurourol Urodyn* 2002;21:194–7.
- [4] Fowler FJ Jr, Barry MJ, Lu-Yao G, Roman A, Wasson J, Wennberg JE. Patient-reported complications and follow-up treatment after radical prostatectomy. The National Medicare Experience: 1988–1990 (updated June 1993). *Urology* 1993;42:622–9.
- [5] Klingler HC, Marberger M. Incontinence after radical prostatectomy: surgical treatment options. *Curr Opin Urol* 2006;16:60–4.
- [6] Hajivassilou CA. A review of the complications and results of the implantation of the AMS artificial urinary sphincter. *Eur Urol* 1999;35:36–44.
- [7] Montague D, Angermeier, Paolone D. Long term continence and patient satisfaction after artificial sphincter implantation

- for urinary incontinence after prostatectomy. *J Urol* 2001; 166:547–9.
- [8] Hubner WA, Schlarp OM. Treatment of incontinence after prostatectomy using a new minimally invasive device: adjustable continence therapy. *BJU Int* 2005;96:587–94.
- [9] Trigo Rocha F, Mendes Gomes C, Lima Pompeo AC, Marmo Lucon A, Arap S. Prospective study evaluating efficacy and safety of adjustable continence therapy (ProACT), for post radical prostatectomy urinary incontinence. *Urology* 2006;67:965–9.
- [10] Wagner TH, Patrick DL, Bavendam T, Martin M, Buesching D. Quality of life of people with urinary incontinence; development of a new measure. *Urology* 1996;1:67–72.
- [11] Yalcin I, Bump RC. Validation of two global impression questionnaires for incontinence. *Am J Obstet Gynecol* 2004; 189:98–101.
- [12] Frazer MI, Sutherst JR, Holland EFN. Visual analogue scores and urinary incontinence. *Br Med J (Clin Res Ed)* 1987;295:582.
- [13] Venn SN, Greenwell TJ, Mundy AR. The long term outcome of artificial urinary sphincters. *J Urol* 2000;164: 702–7.
- [14] Stern JA, Clemens JQ, Tiplitsky SI, Matschke HM, Jain P, Schaeffer AJ. Long-term results of the bulbourethral sling procedure. *J Urol* 2005;173:1654–6.
- [15] Kylmala T, Tainio H, Raitanen M, Tammela T. Treatment of post operative male urinary incontinence using transurethral macropastique injections. *J Endourol* 2003;17:113–5.
- [16] Sousa A, Mantovani F, Moretti M, Condelidis N, Neymeyer J, Noguera R. Male Remeex System (MRS) for the treatment of SUI: a multicentric trial. International Continence Society Annual Meeting, Montréal, Canada, September 2005, Abstract 465.