

Implantation of an Adjustable Continence Therapy System Using Local Anesthesia in Patients With Post-Radical Prostatectomy Stress Urinary Incontinence: A Pilot Study

Andrea Gregori,* Stefano Galli, Ioannis Goumas Kartalas, Francesco Scieri, Silvio Stener, Giacomo Piero Incarbone and Franco Gaboardi

From the Department of Urologic Surgery, "Luigi Sacco" University Medical Center, Milan, Italy

Purpose: We evaluated whether transrectal ultrasound guided ProACT™ system implantation in patients under local anesthesia and with stress urinary incontinence after radical prostatectomy is feasible in a day hospital setting, and is safe and well tolerated.

Materials and Methods: The procedure was used in 11 consecutive patients (mean age 69.9 years) with stress urinary incontinence after undergoing radical prostatectomy between November 2006 and July 2007. The ProACT system was implanted with a transrectal ultrasound guided procedure after administration of local anesthesia (40 ml ropivacaine 7.5 mg/ml) in perineal skin, subcutaneous tissue, pelvic diaphragm and laterally to the anastomosis. During surgery any reason for discomfort was collected. Pain was evaluated with the visual analogue scale, Numeric Pain Intensity Scale and Simple Descriptive Pain Intensity Scale. Transrectal ultrasound was performed 7 days after surgery to exclude device migrations due to early patient mobilization.

Results: The ProACT systems were successfully implanted in all patients under local anesthesia without any need for general anesthesia, and without perioperative surgical or anesthesia related complications. Subjective discomfort was minimal. Mean visual analogue scale was 13 mm (range 0 to 28). Mean Numeric Pain Intensity Scale was 1.4 points (range 0 to 4). On the Simple Descriptive Pain Intensity Scale 4 patients (36.3%) reported no pain, 5 (45.5%) reported mild pain and 2 (18.2%) reported moderate pain. Discharge from the hospital was possible for all patients after 6 hours. All transrectal ultrasound performed after 7 days excluded balloon migrations.

Conclusions: Transrectal ultrasound guided ProACT system implantation with the patient under local anesthesia only is feasible, safe, well tolerated and may be performed as a day surgery procedure.

Key Words: anesthesia, local; prostatectomy; prostheses and implants; ultrasonography; urinary incontinence

Treatment for SUI after radical prostatectomy with adjustable continence therapy systems has been described with promising clinical results.¹⁻⁴ ProACT system implantation is performed using fluoroscopy¹⁻³ or transrectal ultrasonography⁴ for guidance with the patient under general anesthesia or spinal blockage. The objectives of this pilot study were to evaluate if TRUS guided ProACT system implantation using local anesthesia in patients with SUI after RP was feasible, safe and well tolerated.

MATERIALS AND METHODS

Patients

After obtaining institutional review board approval the procedure was used in 11 unselected consecutive patients (mean age 69.9 years, range 64 to 77) with post-RP urodynamic intrinsic sphincter deficiency without detrusor overactivity between November 2006 and July 2007.

Before treatment all patients were evaluated with a complete medical history, physical examination, chest x-ray, abdominopelvic computerized tomography, bone scan, prostate specific antigen and liver function tests to rule out distant metastasis. Flexible cystoscopy and TRUS were used to evaluate the bladder neck, anastomosis and urethra to exclude local recurrences and strictures.

Incontinence was evaluated as the number of PPD used by patients, and categorized as mild—1 or 2, moderate—3 to 5 and severe—greater than 5 PPD. Urodynamic investigations were done to exclude detrusor overactivity or compliance abnormalities, and Valsalva leak point pressure and maximal urethral closing pressure were measured. All patients were also assessed with a 24-hour pad test and with the Wagner et al validated quality of life questionnaire.⁵ Table 1 lists patient demographics.

Patient Preparation

All patients were prepared to receive general or regional anesthesia and agreed to being operated on under local anesthesia only, signing an informed consent form. Patients were advised to take an antiseptic shower and a cleansing enema the night before surgery. Hospital admission was on the day of surgery. Antibiotic intravenous prophylaxis with

Submitted for publication August 23, 2007.

Study received institutional review board approval.

* Correspondence: Via Casati 13, 20052 Monza (Milan), Italy (telephone: +393471197270; FAX: +390239043015; e-mail: greg001@libero.it).

TABLE 1. Patient demographics

No. pts	11
Mean pt age (range)	69.9 (64–77)
Mean mos from RP-ProACT implantation (range)	34 (7–84)
No. previous adjuvant radiotherapy	1
No. previous bladder neck incisions	1
No. previous urethral bulking injections	1
No. incontinence:	
Mild	2
Moderate	7
Severe	2
Mean gm 24-hr pad test (range)	543.6 (80–1,300)
Mean cm H ₂ O Valsalva leak point pressure (range)	51 (15–190)
Mean cm H ₂ O max urethral closing pressure (range)	43 (21–85)
Mean QOL score \pm SD	43 \pm 11.5

a single 2 gm dose of ceftriaxone was intravenously administered on call to the operating room. Analgesic therapy with 100 mg pethidine (meperidine) was intramuscularly administered on call to the operating room to prevent central sensitization.⁶ During the procedure heart rate, arterial pressure and peripheral oxygen saturation were monitored, and an anesthesiologist was available in case of an undesired event or if general anesthesia was required.

Operative Technique

The patient is placed in the lithotomy position, and the lower abdomen, genitals, perineum and the perianal area are disinfected. A 16Fr Foley catheter is inserted in the bladder to fill it with 50 ml saline solution, and clearly visualize the urethra and the bladder neck with TRUS. The scrotum is held above the perineum with tape. The anal ring is separated by the perineum with a drape, and TRUS is performed using a 7.5 MHz linear and small convex probe.

Superficial local anesthesia with 10 ml ropivacaine 7.5 mg/ml is bilaterally administered with a regular 20 gauge needle in skin and subcutaneous tissue at 1 to 2 cm around the intended perineal incisions. Two horizontal 5 to 10 mm skin incisions are made in the perineum approximately 1 cm lateral to the median line and 1.5 cm above the rectum. Deep local anesthesia with 20 ml ropivacaine 7.5 mg/ml is bilaterally administered under TRUS guidance with a 20 gauge spinal needle inserted through the skin incisions and directed laterally to the vesicourethral anastomosis (fig. 1).

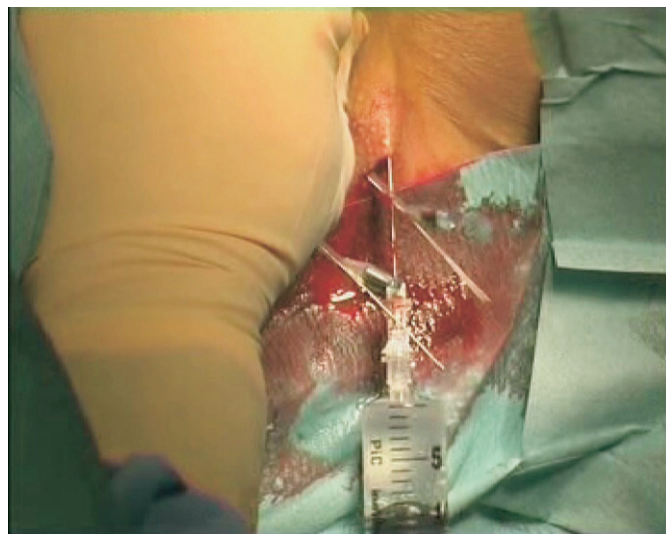
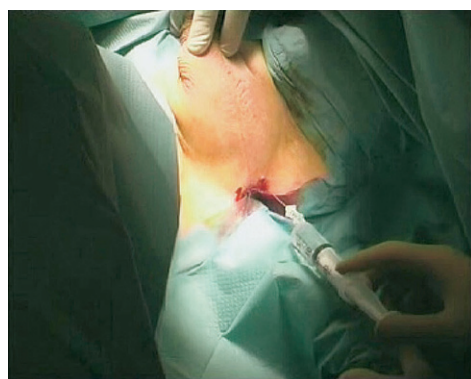

FIG. 2. Administration of superficial local anesthesia in subcutaneous parasacrotal tissue where tubes and titanium ports of ProACT system are then placed.

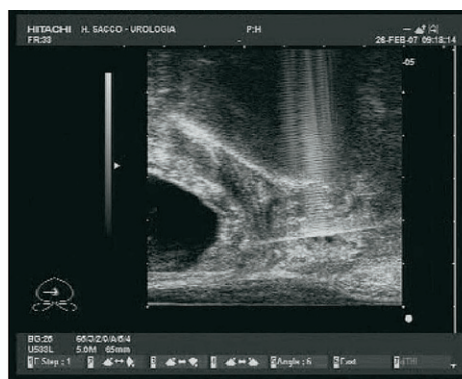
The anesthetic is released along the needle path in the subcutaneous tissue, in the pelvic diaphragm and laterally to the anastomosis creating the space for the ProACT balloon with a mechanism of hydrodissection. The anesthesia requires approximately 15 minutes to be administered and be effective. During the operation patients are encouraged to report any degree of discomfort to enable timely additional infiltration with the local anesthetic.

The ProACT balloons are then placed with the TRUS guided technique, as previously described,⁴ and inflated with 1 ml 0.9% saline solution. After that, superficial local anesthesia with 10 ml ropivacaine 7.5 mg/ml is bilaterally administered with a 20 gauge spinal needle in the subcutaneous parasacrotal tissue where the tubes and the titanium ports of the ProACT system should be placed (fig. 2). After tube and port placement the incisions are closed in 2 layers with 4-zero resorbable sutures, and the Foley catheter is removed.

The patient leaves the operating room, returning directly to the ward without dietary restrictions. Discharge home is planned after approximately 6 hours and a suprapubic ul-



A



B

FIG. 1. Administration of deep local anesthesia under TRUS guidance with 20 gauge spinal needle inserted through skin incisions and directed laterally to vesicourethral anastomosis. A, intraoperative image. B, TRUS paramedian sagittal view.

trasound is performed to rule out urinary retention. A 5-day course of antibacterial prophylaxis is given with the oral fluoroquinolone levofloxacin.

Discomfort and Pain Assessment

During all the steps of the procedure patients were asked to report any reason of subjective discomfort. Before discharge from the hospital patients were asked if they were satisfied with having the operation done under local anesthesia, if they would repeat the procedure and if they would recommend this operation to their families or friends.

Immediately after the procedure patients were asked to complete 3 validated pain intensity scales.⁷⁻⁹ The VAS consists of a 100 mm horizontal line with no pain at one end and worst possible pain at the other end. The patient marks the line and the length is measured in mm with a ruler. The NPIS is composed of a 0 to 10 point scale (with zero—no pain and 10—worst possible pain. The SDPIS is composed of the 6 items of no pain, mild pain, moderate pain, severe pain, very severe pain and worst possible pain.

Followup and Postoperative Adjustment of ProACT System

On postoperative day 7 TRUS was performed to exclude balloon migrations due to early mobilization and discharge from the hospital. On postoperative day 30 TRUS was performed to confirm correct placement of the balloons. If the devices were in the correct position and complete continence was not achieved, each balloon was filled with 1 ml 0.9% saline. TRUS and balloon adjustments were done every 30 days until complete continence or clinical improvement was achieved at a maximum filling volume of 8 ml per balloon. When balloon adjustments were completed patients were assessed with a 24-hour pad test (less than 8 gm—dry), with the number of PPD used (0 to 1 safety PPD—dry, more than 50% PPD reduction—improved, less than 50% PPD reduction—failure) and with the QOL questionnaire.⁵

RESULTS

Operative Results

The ProACT systems were successfully implanted in all patients under local anesthesia without any need for general

anesthesia. The time to complete the overall procedure ranged from 30 to 50 minutes. No patients had inadequate analgesia which required additional infiltration with local anesthetics. We noted that hydrodissection provided by the anesthetic release laterally to the anastomosis was helpful for creating the space for the ProACT balloon placement. All patients retained the capability of adequate verbal communication with the staff in the operating room. We did not observe perioperative surgical or anesthesia related complications and urinary retention after catheter removal. All patients resumed a full, normal diet within hours after surgery and discharge from the hospital was possible for all patients after 6 hours. No patients required postoperative analgesia. All TRUS performed after 7 days excluded balloon migrations.

Subjective Discomfort

There were 7 patients who reported mild discomfort during catheter and transrectal ultrasound probe insertion. All patients reported mild burning during the administration of local anesthesia in skin and subcutaneous tissue, and mild discomfort during administration of local anesthesia in the pelvic diaphragm. No patients reported any discomfort during administration of local anesthesia around the vesicourethral anastomosis. Finally 1 patient reported mild discomfort due to the time in the lithotomy position.

Pain Intensity Scales

Mean VAS was 13 mm (range 0 to 28). Mean NPIS was 1.4 points (range 0 to 4). For the SDPIS 4 patients (36.3%) reported no pain, 5 (45.5%) reported mild pain and 2 (18.2%) reported moderate pain.

Patient Satisfaction

All patients declared they were satisfied with having the operation done under local anesthesia. All patients would choose to have the procedure again, and would recommend it to their families and friends.

Clinical Outcome Data

Table 2 shows outcome data in this series, although this was not one of the aims of this report. Mean followup was 8

TABLE 2. Preliminary outcome data

Pt No.	Preop Incontinence Degree	Preop 24-Hr Pad Test (gm)	Preop PPD	Preop QOL Score ⁵	No. Balloon Adjustments	Postop 24-Hr Pad Test (gm)	Outcome (based on PPD)	Postop QOL Score ⁵
1	Moderate	700	3	57	5	0	Dry	100
2	Moderate	650	3	45	7	Less than 8	Dry	88
3	Moderate	700	4	36	4	Less than 8	Dry	86
4*	Moderate	500	4	45	4	Not available, balloon adjustments ongoing	Improved	Not available, balloon adjustments ongoing
5	Mild	80	2	60	3	20	Improved	68
6†	Moderate	200	3	43	7	50	Improved	75
7‡	Severe	1,200	8	22	5	Less than 8	Dry	84
8	Moderate	200	3	36	2	0	Dry	95
9§	Moderate	300	5	57	5	Less than 8	Dry	76
10‡	Mild	150	2	39	3	Not available, balloon adjustments ongoing	Improved	Not available, balloon adjustments ongoing
11	Severe	1,300	7	33	3	0	Dry	93

* Balloon adjustment temporarily interrupted for lung cancer treatment.

† Previous radiotherapy and bladder neck incision.

‡ Balloon adjustments ongoing.

§ Previous urethral bulking injection.

months (range 4 to 12). After a mean of 4.3 balloon adjustments (range 2 to 7), 6 patients (63.6%) were dry while 4 (36.4%) had improvement and no one had treatment failure. The mean QOL score increased from 43 (± 10.5) to 85 (± 10.4).⁵ During followup we did not observe complications such as erosion, migration or device failure.

DISCUSSION

Male SUI is a challenging problem for men following RP. Persistent post-RP SUI (after 1 year) affects 2% to 5% of patients.¹⁰ Implantation of an artificial urinary sphincter is associated with continence and satisfaction rates in approximately 90% of refractory post-RP SUI cases, and currently remains the reference treatment.¹¹

However, the artificial urinary sphincter is expensive and requires a complex surgical procedure which may be associated with significant complication and revision rates. In fact, surgical revision or substitution of the device may be required in up to 40% of cases due to mechanical failures, infections or early and late erosions.^{12–15}

Treatment of post-RP SUI with the minimally invasive ProACT system was first described by Hubner and Schlarp,¹ Trigo-Rocha et al² and by us⁴ with interesting initial clinical results. The implantation procedure was performed with the patient under general anesthesia or spinal blockage.

Reasons to develop ProACT system implantation with the patient under local anesthesia in a day hospital setting include quick recovery after surgery, fast return to a normal diet, decreased use of anesthesia resources, treatment of patients in poor conditions to receive general anesthesia due to severe comorbidity and cost advantages. To our knowledge this is the first report on ProACT implantation in patients under local anesthesia.

Our data suggest that TRUS guided ProACT implantation in patients under local anesthesia with the analgesic effect of pethidine is feasible, safe and well tolerated. Feasibility was demonstrated by the fact that all the procedures were always completed with the patient under local anesthesia without any need for general anesthesia. No perioperative complications or device migrations due to early mobilization occurred suggesting the safety of the technique.

Data regarding subjective discomfort, pain intensity scales and patient approval are satisfactory. In fact, discomfort of catheter and transrectal ultrasound probe insertion is minimal, and generally well tolerated by patients who underwent RP and 1 or more TRUS and an indwelling catheter. Burning and discomfort during local anesthetic administration were minimal as well.

Objective data from validated pain scales (mean VAS 13 mm, mean NPIS 1.4 points, moderate pain in only 18% of cases) may be considered more than satisfactory.⁸ During postoperative balloon adjustments patients just feel minimal discomfort during the percutaneous access to the 2 titanium ports with a 23 gauge needle, which is performed without the patient under anesthesia.⁴

Preliminary outcome data are promising and similar to those previously reported by other authors.^{1–3} The technique combines the advantages of TRUS guided ProACT implantation (excellent imaging of the anatomical landmarks during the entire procedure without radiation exposure) with those of a day surgery procedure with the patient under local anesthesia (quick recovery after surgery, fast

return to a normal diet, decreased use of anesthesia and operating room resources, treatment of patients unfit to receive general anesthesia due to severe comorbidity and cost advantages). Furthermore, local anesthesia is precisely administered under TRUS guidance to obtain an accurate analgesia. Finally the anesthetic release laterally to the anastomosis provides the further advantage of space creation for ProACT balloon placement by hydrodissection.

When local anesthesia is used operative times are longer (approximately 15 minutes) compared to procedures performed using spinal or general anesthesia.⁴ This is due to local anesthetic administration and the time for effectiveness of pain control. However, the operating room time is similar because if local anesthesia is used time is not taken for spinal anesthesia administration or intubation and extubation.

CONCLUSIONS

Our data indicate that TRUS guided ProACT system implantation with the patient under local anesthesia only is feasible, safe, well tolerated and may be performed as a day surgery procedure. However, our pilot study should be still considered a technical report and the limits of the technique must still be defined in a larger population, with different drug combinations and by other investigators.

Abbreviations and Acronyms

NPIS	=	Numeric Pain Intensity Scale
PPD	=	pads per day
QOL	=	quality of life
RP	=	radical prostatectomy
SDPIS	=	Simple Descriptive Pain Intensity Scale
SUI	=	stress urinary incontinence
TRUS	=	transrectal ultrasound
VAS	=	visual analogue scale

REFERENCES

1. Hubner WA and Schlarp OM: Treatment of incontinence after prostatectomy using a new minimally invasive device: adjustable continence therapy. *BJU Int* 2005; **96**: 587.
2. Trigo-Rocha F, Gomes CM, Pompeo AC, Lucon AM and Arap S: Prospective study evaluating efficacy and safety of Adjustable Continence Therapy (ProACT) for post radical prostatectomy urinary incontinence. *Urology* 2006; **67**: 965.
3. Hubner WA and Schlarp OM: Adjustable continence therapy (ProACT™): evolution of the surgical technique and comparison of the original 50 patients with the most recent 50 patients at a single centre. *Eur Urol* 2007; **52**: 680.
4. Gregori A, Simonato A, Lissiani A, Scieri F, Rossi R and Gaibardi F: Transrectal ultrasound guided implantation of the ProACT adjustable continence therapy system in patients with post-radical prostatectomy stress urinary incontinence: a pilot study. *J Urol* 2006; **176**: 2109.
5. Wagner TH, Patrick DL, Bavendam TG, Martin ML and Buesching DP: Quality of life of persons with urinary incontinence: development of a new measure. *Urology* 1996; **47**: 67.
6. Woolf CJ and Chong MS: Pre-emptive analgesia—treating postoperative pain by preventing the establishment of central sensitisation. *Anesth Analg* 1993; **77**: 362.
7. Scott J and Huskisson EC: Graphic representation of pain. *Pain* 1976; **2**: 175.

8. Heid F and Jage J: The treatment of pain in urology. *BJU Int* 2002; **90**: 481.
9. Gordon DB, Pellino TA, Miaskowski C, McNeill JA, Paice JA, Laferriere D et al: A 10-year review of quality improvement monitoring in pain management: recommendations for standardized outcome measures. *Pain Manag Nurs* 2002; **3**: 116.
10. Peyromaure M, Ravery V and Boccon-Gibod L: The management of stress urinary incontinence after radical prostatectomy. *BJU Int* 2002; **90**: 155.
11. Venn SN, Greenwell TJ and Mundy AR: The long-term outcome of artificial urinary sphincters. *J Urol* 2000; **164**: 702.
12. Fleshner N and Herschorn S: The artificial urinary sphincter for post-radical prostatectomy incontinence: impact on urinary symptoms and quality of life. *J Urol* 1996; **155**: 1260.
13. Haab F, Trockman BA, Zimmern PE and Leach GE: Quality of life and continence assessment of the artificial urinary sphincter in men with minimum 3.5 years of followup. *J Urol* 1997; **158**: 435.
14. Litwiller SE, Kim KB, Fone PD, White RW and Stone AR: Post-prostatectomy incontinence and the artificial urinary sphincter: a long-term study of patient satisfaction and criteria for success. *J Urol* 1996; **156**: 1975.
15. Carlson KV and Nitti VW: Prevention and management of incontinence following radical prostatectomy. *Urol Clin North Am* 2001; **28**: 595.