

Adjustable continence therapy for the treatment of urinary incontinence after radical cystectomy and orthotopic neobladder in women

Cássio Riccetto · Paulo Palma · Viviane Herrmann ·
Walter Silva Jr. · Victor Leitão ·
Nelson Rodrigues Netto Jr.

Received: 30 August 2006 / Accepted: 26 November 2006
© International Urogynecology Journal 2007

Abstract The management of urinary incontinence after radical cystectomy and orthotopic neobladder reconstruction is a very challenging situation. We report on a patient that developed a neobladder-urethro-vaginal fistula successfully treated but resulting in severe urinary incontinence that was cured after the periurethral insertion of adjustable silicone balloons.

Keywords Neobladder · Urinary incontinence · Adjustable continence therapy

Introduction

Bladder carcinoma with muscle invasion is classically treated by radical cystectomy. In women, the uterus and both ovaries are also removed. The reported risk of urinary incontinence after radical cystectomy with neobladder is between 5 and 15% [1, 2]. Treatment of urinary incontinence in these cases is still a challenge with no standardized surgical technique available.

Case report

A 55-year-old woman with a unifocal 3-cm diameter invasive papillary urothelial carcinoma (pT2) in bladder

C. Riccetto · P. Palma (✉) · W. Silva Jr. · V. Leitão ·
N. R. Netto Jr.

Division of Urology, University of Campinas, UNICAMP,
Sao Paulo, Brazil
e-mail: ppalma@uol.com.br

V. Herrmann
Division of Gynecology, University of Campinas, UNICAMP,
Sao Paulo, Brazil

base was submitted to a radical cystectomy and ileal neobladder reconstruction of the urinary tract using the Studer technique [3]. Anastomosis between the reservoir and the urethra was performed in the usual manner with 2.0 polyglactin sutures. The patient was kept with a urethral catheter for 21 days and neocystostomy up to the 28th postoperative day. After removal of the catheters, she evolved with stress urinary incontinence requiring four pads per day. The patient underwent pelvic floor training for 12 weeks with no improvement. A multichannel videourodynamics was conducted, demonstrating a 280-ml reservoir with normal compliance, with no detrusor contractions. Valsalva leak-point pressure was 55 cm H₂O. A periurethral implant of the adjustable continent therapy device (ACTTM-Uromedica, Plymouth, MN, USA) was proposed.

The ACTTM kit consists of two silicon balloons connected to titanium portals for infusion of diluted contrast material. Each balloon should be inserted at the level of the bladder neck. The procedure was performed under spinal anesthesia. The patient was placed in lithotomy position, and cystoscopy was performed to assess the condition of the implant site. The bladder was previously filled with 150 ml of saline and contrast material, and a Foley catheter was maintained during the entire procedure to identify the bladder neck. Two incisions were made on each side of the labia majora at level of the urethral meatus. The trocar was then introduced through the right and left incision under fluoroscopy towards the neobladder-urethral anastomosis, parallel to the urethra, at 3 o'clock and 9 o'clock positions, respectively (Fig. 1). Each balloon was filled with 2 ml of diluted contrast material. The port was positioned in the subcutaneous tissue of the labia majora so that any adjustments could easily be made. At the end of the procedure, the bladder was emptied, and no catheter

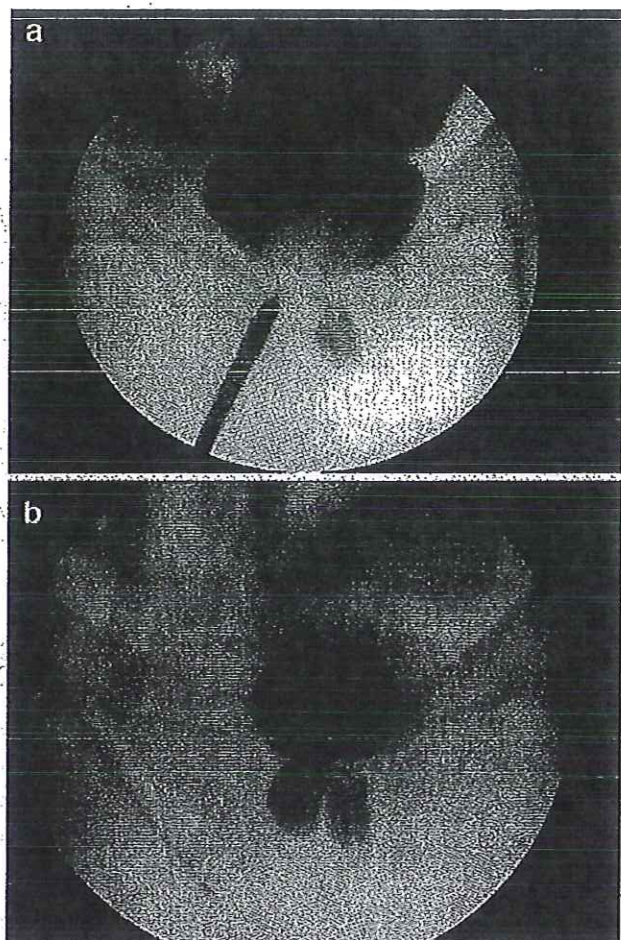
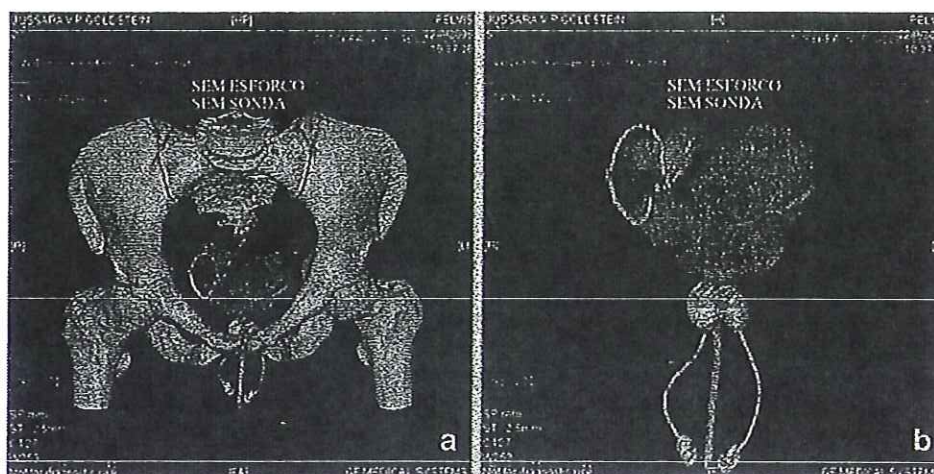


Fig. 1 a Intra-operative fluoroscopy showing the trocar introduced through the right incision at 3 o'clock position, parallel to urethra. b At the end of the procedure, both balloons are located, close to the neobladder-urethral anastomosis (Foley balloon was also inflated with contrast media for easy demonstration of implantation site)

was left in place. Spontaneous voiding with no significant residuals was noted, and the patient was discharged 24 h after the procedure.

Fig. 2 Magnetic resonance demonstrating the relationship among the balloons, the urethra and the reservoir. a Panoramic view. b Detail



The patient presented partial improvement of the urinary incontinence so that each balloon was adjusted with additional 2 ml of saline under local anesthesia at 4 weeks and 2 ml at 8 weeks after the implant. The patient was able to remain continent during the day with eventual urine loss during the night.

Neobladder urodynamics disclosed no involuntary contractions, so that this minor leakage could be probably due to either rhabdosphincter relaxation or overflow.

No infection, rejection of dyspareunia was observed. She was submitted to a magnetic resonance 3 months after the procedure, which showed the relationship among the balloons, the urethra and the reservoir (Fig. 2).

Discussion

Radical cystectomy with ileal neobladder urinary tract reconstruction has proven to be a good alternative in the treatment of women with invasive bladder carcinoma without systemic disease or invasion [1–4]. Some complications of this procedure include chronic urinary retention requiring clean intermittent catheterization, calculus formation in the reservoir, neobladder–vaginal fistula and urinary incontinence [1, 4].

After creating the neobladder, urinary continence depends on a low-pressure reservoir with good capacity and compliance as well as adequate urethral sphincter function, especially through the preservation of the inferior hypogastric plexus fibers innervating the vagina and the urethra [4]. A careful dissection of the pubocervical fascia is thought to play an important role in the functional integrity of the urethral sphincter mechanism [2].

Urinary incontinence after radical cystectomy and neobladder ranges from 5 to 15% [1, 6]. Stein et al. [1] considered that the worsening of the night symptoms may be due to the reduced voluntary tonus of the muscle

elevator of the anus. Colleselli et al. [5] suggested that the preservation of the distal urethra and its innervation was responsible for the continence after cystectomy.

The treatment of choice for urinary incontinence in women after radical cystectomy and neobladder is still a controversial subject. Despite the trend to use minimally invasive treatments, there are few reports in the literature on the use of injectable agents with variable success rates.

Wilson et al. [6] treated 11 patients with collagen injections and one with nonabsorbable pyrolytic carbon-coated beads. At 22 months follow-up, 16.7% of the patients were continent, 33% presented a reduction in the number of pads used, and 50% demonstrated no improvement. Tchetchgen et al. [7] used transurethral collagen to treat three incontinent patients after neobladder procedure and observed that despite the improvement presented by all patients after the first application, the procedure needed to be repeated in two of them. After 8 months, only one patient was continent, one was incontinent, and one referred some improvement.

Queck et al. [8] treated four patients with post-neobladder incontinence with slings. Two patients underwent aponeurotic retropubic slings. A bone anchored dermal graft was used in the other two patients. The patients who underwent the retropubic sling surgery presented neobladder or small intestine perforations, and one patient died due to septic complications caused by enteric fistula. Patients treated with infrapubic bone anchors developed urinary retention and needed clean intermittent catheterization.

Hübner and Schlarp [9] had previously described the use of the adjustable continent therapy device (Pro-ACT™) in 117 men with post-prostatectomy urinary incontinence. After a mean follow-up of 13 months, the authors observed that 92% of the patients reported a significant improvement, whereas 67% achieved complete continence based on the pad test. Readjustments were needed in 96% of the patients, with a median of three adjustments required per patient (0 to 15). The mean volume injected per balloon was 3.5 ml (1 to 10 ml), and 6% of the patients presented with some degree of post-surgery urinary retention solved after partial emptying of the balloon. The authors proposed a 4 to 6 weeks interval for readjustment of the balloon so that adequate fixation of the device occurs due to the fibrosis around the device.

Pacetta et al. [10] described the use of ACT for selected cases of female incontinence.

This was the first description on the use of this device for the treatment of urinary incontinence post radical cystectomy and orthotopic neobladder in a female patient. The possibility of adjusting volume within each balloon to achieve ideal coaptation and the use of an access different from that used in the initial oncological procedure make this method an attractive alternative for female patients with stress urinary incontinence post cystectomy and orthotopic neobladder.

References

- Stein JP, Grossfeld GD, Freeman JA, Esrig D, Ginsberg DA, Cote RJ, Skinner EC, Boyd SD, Lieskovsky G, Skinner DG (1997) Orthotopic lower urinary tract reconstruction in women using the Kock ileal neobladder: updated experience in 34 patients. *J Urol* 158(2):400–405
- Hautmann RE, Paiss T, De Petriconi R (1996) The ileal neobladder in women: 9 years of experience with 18 patients. *J Urol* 155(1):76–81
- Stein JP, Ginsberg DA, Skinner DG (2002) Indications and technique of the orthotopic neobladder in women. *Urol Clin North Am* 29(3):725–732
- Nesrallah LJ, Almeida FG, Dall'Oglio MF, Nesrallah AJ, Srougi M (2005) Experience with the orthotopic ileal neobladder in women: a mid-term follow up. *BJU Int* 95(7):1045–1047
- Colleselli K, Strasser H, Moriggl B, Eder R, Strasser H, Poisel S, Bartsch G (1998) The female urethra: a morphological and topographical study. *J Urol* 160 (1):49–54
- Wilson S, Queck ML, Ginsberg DA (2004) Transurethral injection of bulking agents for stress urinary incontinence following orthotopic neobladder reconstruction in women. *J Urol* 172(1):244–246
- Tchetchgen MB, Sanda MG, Montie JE, Faerber GJ (2002) Collagen injection for the treatment of incontinence after cystectomy and orthotopic neobladder reconstruction in women. *J Urol* 163(1):212–214
- Queck ML, Ginsberg DA, Wilson S, Skinner EC, Stein JP, Skinner DG (2004) Pubovaginal slings for stress urinary incontinence following radical cystectomy and orthotopic neobladder reconstruction in women. *J Urol* 172(1):219–221
- Hübner WA, Schlarp OM (2005) Treatment of incontinence after prostatectomy using a new minimally invasive device: adjustable continence therapy. *BJU Int* 96(4):587–594
- Pacetta AM, Sadi MV, Dametto PN (2005) Terapia Ajustável de continência In: Palma P, Netto NR Jr, Uroginecologia ilustrada, Editora Roca, São Paulo, pp 113–115